

## Anti-inflammatory and Hepatoprotective Activities of *Trigonella foenum-graecum* L.

Ahmet Cihat Öner<sup>a</sup> Ufuk Mercan<sup>a</sup> Hatice Öntürk<sup>b</sup> Nureddin Cengiz<sup>c</sup> Remzi Erten<sup>d</sup>,  
Hanefi Özbek<sup>e\*</sup>

<sup>a</sup> *Yüzüncü Yıl University, Faculty of Veterinary, Department of Pharmacology-Toxicology, Van-Turkey,*

<sup>b</sup> *Bitlis Eren University, Health College, Bitlis-Turkey,*

<sup>c</sup> *Yüzüncü Yıl University, Medical School, Department of Histology-Embryology, Van-Turkey,*

<sup>d</sup> *Yüzüncü Yıl University, Medical School, Department of Pathology, Van-Turkey,*

<sup>e</sup> *Ministry of Health, General Directorate of Pharmaceuticals and Pharmacies, Ankara-Turkey.*

### Summary

The aim of this study was to investigate anti-inflammatory and hepatoprotective activities of *Trigonella foenum graecum* L. (TFG). *Anti-inflammatory activity:* Control group was administered saline solution and reference group was administered indomethacin. TFG groups were injected TFG:olive oil (1:4) in doses of 0.1 mL/kg (TFG-I), 0.5 mL/kg (TFG-II) and 1.0 mL/kg (TFG-III). Before the injections and three hours after the injections the volume of right hind-paw of rats was measured using a plethysmometer. *Hepatoprotective activity:* The hepatotoxicity was induced by carbon tetrachloride (CCl<sub>4</sub>) administration. Control group and CCl<sub>4</sub> group received saline solution and 0.8 mL/kg CCl<sub>4</sub>:olive oil (1:1) respectively for seven days. TFG group and silibinin group (reference group) received TFG:olive oil (1:4) in doses of 0.1 mL/kg and 50 mg/kg, respectively for seven days. Blood samples were collected on the 8th day and the liver was extracted after the animals were killed. TFG had an anti-inflammatory effect matching to that of control group at all doses. It was found that reduction in the inflammation was 93.20% with indomethacin, 31.70% with TFG-I, 43.47% with TFG-II and 44.95% with TFG-III. Median effective dose (ED<sub>50</sub>) value of TFG was found to be 0.0645 mL/kg. TFG significantly reduced the serum alanine aminotransferase and aspartate aminotransferase levels when compared to CCl<sub>4</sub> group. The histopathological findings showed a significant difference between the TFG and CCl<sub>4</sub> groups. The results showed that TFG had considerable anti-inflammatory and hepatoprotective activities.

**Key Words:** *Trigonella foenum-graecum* L., anti-inflammmtory activity, hepatoprotective activity, rat.

\*Corresponding author: [hanefiozbek@hotmail.com](mailto:hanefiozbek@hotmail.com) (Dr. Hanefi Özbek) Fax:+90 432 216 83 52

## Introduction

*Trigonella foenum-graecum* L. (TFG, fenugreek), a member of the Leguminosae family, is a perennial plant which grows up to 10-50 cm height and it is widely distributed in Agypt, India, Greece, Lebanon, Spain, Italy, France and Turkey. This plant grows widely in Middle Anatolia (1, 2). *Trigonella foenum-graecum* L. are used as folk medicine due to their hepatoprotective, anti-inflammatory, hypoglycemic, expectorant and laxative properties (2-4).

Kavirasan and Anuradha reported that TFG seed polyphenolic extract acts as a protective agent against ethanol-induced abnormalities in the liver. The effects of TFG are comparable with those of a known hepatoprotective agent, silymarin (5). Dixit et al demonstrated antioxidant activity in germinated TFG seeds (6). Balaraman et al reported that methanolic extract of TFG seed exhibits a significant antihypertensive effect (7). Bin-Hafeez et al reported that TFG showed a stimulatory effect on immune functions in mice (8). Some researches showed that the extract of TFG leaves produces antinociceptive effects (9, 10).

In the present study, we investigated the anti-inflammatory and hepatoprotective activities of diethyl ether extract of *Trigonella foenum-graecum* L. seeds, administered intraperitoneally to rats.

## Materials and Methods

### Plant material

*Trigonella foenum-graecum* L. seeds used were purchased in the month of June from the local market at Van (Turkey) and identified by Dr. Fevzi Özgökçe (Department of Botany, Yüzüncü Yıl University, Turkey). Voucher specimens for the plant seeds have been deposited in Pharmacology Laboratory of Yüzüncü Yıl University (B-23). The dried seeds of *Trigonella foenum-graecum* L. were finely grounded in an electrical grinder and extracted by soxhlet apparatus (Ildam, Turkey) with diethyl ether (40-50°C) until completely exhausted. Diethyl ether was evaporated under reduced pressure by a rotary evaporator (IKA-WERKE RV 05-ST rotavapor, Germany). The yield was determined as 1.6 % (w/v).

### Animals

Female and male Sprague-Dawley rats weighing 100-180 g were used in these experiments. The animals were housed at room temperature (20±2 °C) in standard cages with standard pellet food and water *ad libitum*, in rooms lit in a rhythm of 12 h light, 12 hours dark and kept under controlled environment according to the standard operating procedures of the animal house with approval of animal ethics committee. Prior to administration of the drugs, the animals were fasted for 18 h with free access to drinking water.

### Chemicals

Lambda-carrageenan Type IV, indomethacin and silibinin were obtained from Sigma (Steinheim, Germany), carbon tetrachloride (CCl<sub>4</sub>) was obtained from Merck (Darmstadt, Germany) and olive oil was obtained from Fluka (Steinheim, Germany). Lambda-carrageenan was dissolved in distilled water (w/v), silibinin and indomethacin were dissolved in ethyl alcohol (w/v), CCl<sub>4</sub> and TFG were dissolved in olive oil (v/v) (1:1 and 1:4 dilutions, respectively).

### Anti-inflammatory activity

The method of Winter et al with slight modification was used (11). Thirty rats of either sex were divided into five groups of six animals each. Inflammation of the hind paw was induced by injecting 0.05 mL fresh lambda-carrageenan (phlogistic agent) into the subplantar surface of the right hind paw. The experimental groups were as follows (n=6):

- Group 1: saline (0.9 % isotonic saline solution, ISS), 0.1 mL, po,  
 Group 2: Indomethacin (3 mg/kg) (12), ip,  
 Group 3: TFG:olive oil (1:4), (0.25 mL/kg), ip,  
 Group 4: TFG: olive oil (1:4), (0.5 mL/kg), ip,  
 Group 5: TFG: olive oil (1:4), (1.0 mL/kg), ip,

These doses of the extract utilized in the current study have been chosen according to Sur et al (13). The measurement of foot volume was accomplished by displacement technique using a plethysmometer (Ugo Basile 7140 plethysmometer, Italy), immediately before and three hours after the injection of the drugs. The inhibition percentage of the inflammatory reaction was determined for each animal by comparison with controls and calculated by the formula (14):

$$I\% = [(1-(dt/dc)] \times 100$$

where *dt* is the difference in paw volume in the drug-treated group and *dc* the difference in paw volume in the control group.

### Hepatoprotective activity

The CCl<sub>4</sub> model described by Handa&Sharma (15) and Shenoy et al (16) was used for scheduling the dose regimen. Intraperitoneal injection of 0.8 mL/kg carbon tetrachloride diluted in olive oil (1:1 dilution) was employed for inducing acute liver toxicity. The experimental groups were as follows (n=6):

- Group 1: saline (0.9 % isotonic saline solution, ISS), 0.1 mL, ip,  
 Group 2: CCl<sub>4</sub>:olive oil (1:1) (0.8 ml/kg), ip,  
 Group 3: Silibinin 50 mg/kg and CCl<sub>4</sub>:olive oil (1:1) (0.8 ml/kg), ip,  
 Group 4: TFG:olive oil (1:4) (0.5 mL/kg) and CCl<sub>4</sub>:olive oil (1:1) (0.8 ml/kg), ip.

The doses of the TFG and silibinin utilized in the current study have been chosen according to Sur et al (13) and Horváth et al (17), respectively. All injections were applied once a day for seven days. Carbontetrachloride and TFG, CCl<sub>4</sub> and silibinin were applied using different injectors. All the animals were observed daily and dead animals were subjected to post-mortem examination to find the cause of death. At the end of the treatment (8<sup>th</sup> day), blood samples were collected by direct cardiac puncture and the serum was used for the assay of marker enzymes, aspartate aminotransferase (AST) and alanine aminotransferase (ALT). Rats were weighted daily throughout the eight days.

The serum AST and ALT concentrations were determined with a commercial kit (Vitros) by Vitros DT60-II Autoanalyzer (USA, Rochester-New York). The livers of the experimental animals were extracted after killing the animals by cervical dislocation and fixed in 10% neutral buffered-formalin prior to routine processing in paraffin-embedded blocks. Sections (4 μm thick) were cut and stained using Hematoxylin-eosin (HE) stain. Histological damage was expressed using the following score system; 0:absent; +:mild; ++:moderate; +++:severe.

### Statistical analysis

All data were expressed as mean ± standard error of the mean (SEM) or as percentages. Analysis of variance (ANOVA) was used for the statistical analysis of data. Dunnett's test, Tukey's HSD test (Tukey's honestly significant difference test) and LSD test (least significant difference test) were used for determining significance. Results with *p*<0.05 were considered as statistically significant.

## Results

## Anti-inflammatory activity

Table 1 shows the results of the anti-inflammatory effect of intraperitoneal administration of TFG on carrageenan paw oedema in rats. All doses of TFG caused a significant reduction in paw oedema. There was no difference between the effects of TFG at three doses ( $p > 0.05$ ). As seen in Table 1, TFG showed anti-inflammatory activity higher than control group, but it did not show so strong effect as indomethacin. Indomethacin (reference drug) produced a significant inhibition (93.20 %). It was found that reduction in the inflammation was 31.70% with TFG-I, 43.47% with TFG-II and 44.95% with TFG-III. Median effective dose ( $ED_{50}$ ) value of TFG was found to be 0.0645 mL/kg.

**Table 1.** Effect of TFG on carrageenan-induced hind paw oedema in rats ( $n=6$ ).

Groups	Dose	Paw edema (mL %)	Inhibition (%)
Control (ISS)	0.1 mL	0.848 ± 0.053	-
Indomethacin	3 mg/kg	0.058 ± 0.149 <sup>a</sup>	93.20
TFG-I	0.05 mL/kg	0.579 ± 0.063 <sup>ab</sup>	31.70
TFG-II	0.10 mL/kg	0.479 ± 0.140 <sup>ab</sup>	43.47
TFG-III	0.20mL/kg	0.467 ± 0.066 <sup>ab</sup>	44.95
<i>F/p value</i>		<i>17.015 / 0.000</i>	

The values represent the mean ± S.E.M. (standard error of the mean).

$ED_{50}$ : 0.0645 mL/kg.

Post-hoc Tukey's HSD (honestly significant difference) test and Dunnet test:

a :  $p < 0.05$  with respect to control (ISS) group,

b :  $p < 0.05$  with respect to indomethacin group.

## Hepatoprotective activity

Levels of serum AST and ALT were markedly elevated in  $CCl_4$  treated animals compared to control animals, as shown in Table 2. Administration of silibinin at a dose of 50 mg/kg remarkably prevented  $CCl_4$  induced elevation of serum enzymes. TFG treated group had significantly lower levels of AST and ALT when compared with the  $CCl_4$ :olive oil group.

**Table 2.** Effect of TFG on serum AST and ALT levels in rats ( $n=6$ ).

Groups	ALT	AST
	Serum (U/L)	Serum (U/L)
Control (ISS)	46.12 ± 5.12	166.23 ± 12.66
$CCl_4$	1094.46 ± 132.24 <sup>a</sup>	1934.37 ± 273.21 <sup>a</sup>
Silibinin + $CCl_4$	178.12 ± 33.12 <sup>b</sup>	584.21 ± 72.23 <sup>ab</sup>
TFG + $CCl_4$	549.60 ± 232.15 <sup>abc</sup>	517.40 ± 231.02 <sup>ab</sup>
<i>F/p Value</i>		<i>32117 / 0.000</i>

The values represent the mean ± S.E.M. (standard error of the mean).

Post-hoc LSD (least significant difference) test:

a :  $p < 0.05$  with respect to control (ISS) group,

b :  $p < 0.05$  with respect to  $CCl_4$  group,

c :  $p < 0.05$  with respect to silibinin group.

**Histopathological examination**

In control group (ISS), liver sections showed normal hepatic parenchyma and stroma. Cell apoptosis was not observed in this group. Liver hepatocyte cords, sinusoids and stroma were histologically normal.

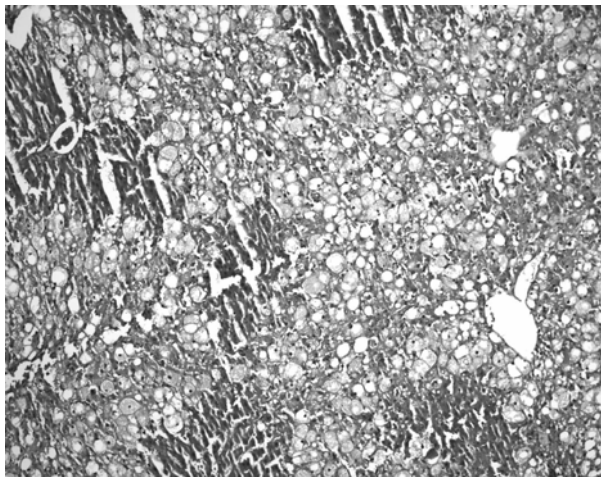
In carbon tetrachloride treated liver, drastic alterations were observed. Histopathological examination demonstrated that CCl<sub>4</sub> (compared to ISS control group) induced ballooning degeneration, centrilobular necrosis, bridging necrosis and apoptosis (acidophilic change) in hepatocytes (Table 3). Ballooned hepatocytes were of different sizes and much larger than normal hepatocytes and occasionally appeared as confluent areas (Fig. 1).

**Table 3.** Histopathological changes in the liver of rats.

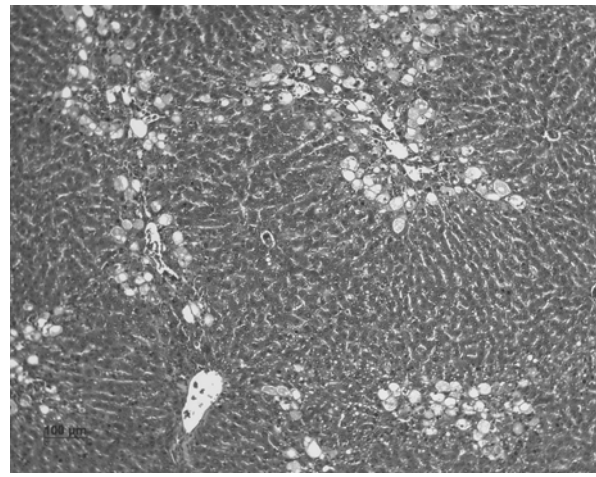
Groups	Microscopic Observation			
	Ballooning degeneration and steatosis	Apoptosis and/or necrosis of hepatocytes	Bridging necrosis	Average score*
ISS	0	0	0	0/6=0.00
CCl <sub>4</sub>	15	14	13	42/6=7.00
Silibinin	7	8	4	19/6=3.17
TFG	10	8	12	30/6=5.00

\* Average score = Total score / n

*Trigonella foenum-graecum* L. or silibinin treated livers showed significant recovery. These changes were minimized by TFG or silibinin treatment (Fig. 2).



**Figure 1.** CCl<sub>4</sub>-induced hepatotoxicity in rats (numerous ballooned hepatocytes are seen in the liver) (Hematoxylin-eosin stain, original magnification, x100).



**Figure 2.** A few ballooned hepatocytes are seen in the liver of the TFG group (Hematoxylin-eosin stain, original magnification, x100).

**Discussion**

The effectiveness of *Trigonella foenum-graecum* L. in inflammation and hepatotoxicity has been especially emphasized among some traditional claims (2-4). Therefore, we studied *Trigonella foenum-graecum* L. pharmacologically and toxicologically for their above mentioned properties.

The results showed that diethyl ether extract of *Trigonella foenum-graecum* L. has anti-inflammatory and hepatoprotective effects. Other studies have demonstrated that several compounds were isolated and identified as N,N'-dicarbazyl, glycerol monopalmitate, stearic acid, beta-sitosteryl glucopyranoside, ethyl-alpha-D-glucopyranoside, D-3-O-methyl-chiroinsitol, sucrose, methyl-protodioscin, methyl-protodeltonin, 26-O-beta-D-glucopyranosyl-(25S)-5 alpha-furostane-2 alpha,3 beta,22 zeta,26-tetraol 3-O-[beta-D-xylopyranosyl (1 --> 6)]-beta-D-glucopyranoside, etc. from the seeds of *Trigonella foenum-graecum* L (18-20). The anti-inflammatory and hepatoprotective effects of the extract may be due to their content listed above.

Kavariasan and Anuradha reported that ethanolic extract of *Trigonella foenum-graecum* L. seeds are protective agent against ethanol-induced abnormalities in the rat liver (5). Ahmadiani et al showed that the TFG leaves extract possesses anti-inflammatory properties in both ip and po administration (10). Our results are in accordance with above mentioned articles.

It is concluded that the diethyl ether extract of *Trigonella foenum-graecum* L. seeds have anti-inflammatory and hepatoprotective effects. The results of the present study support the traditional use of *Trigonella foenum-graecum* L. in inflammation and hepatotoxicity. Further studies are needed to better evaluate these activities and the potential of *Trigonella foenum-graecum* L.

### References

1. Akgül A. Spices Science & Technology. First ed. Ankara-Turkey. Society of Food Technology Publishing, Nr:15, 1993:71-72.
2. Baytop T. Therapy with Medicinal Plants in Turkey. 2<sup>nd</sup> ed. Istanbul-Turkey, Nobel Tip Kitapevleri, 1999:171.
3. Öztürk Y, Başer KHC, Aydın S. Hepatoprotective (antihepatotoxic) plants in Turkey. Proceedings of the 9th Symposium on Plant Drugs Eskisehir-Turkey, 16-19 May 1991:40-50.
4. Pamuk A. The Encyclopedia of Herbal Medicine. Pamuk Yay ve Matb: Istanbul-Turkey, 1998:338, 463.
5. Kavariasan S, Anuradha CV. Fenugreek (*Trigonella foenum graecum*) seed polyphenols protect liver from alcohol toxicity: a role on hepatic detoxification system and apoptosis. Pharmazie 2007;62(4):299-304.
6. Dixit P, Ghaskadbi S, Mohan H, Devasagayam TP. Antioxidant properties of germinated fenugreek seeds. Phytother Res 2005;19(11):977-983.
7. Balaraman R, Dangwal S, Mohan M. Antihypertensive Effect of *Trigonella foenum-graecum* Seeds in Experimentally Induced Hypertension in Rats. Pharm Biol 2006;44(8):568-575.
8. Bin-Hafeez B, Haque R, Parvez S, et al. Immunomodulatory effects of fenugreek (*Trigonella foenum graecum* L.) extract in mice. Int Immunopharmacol 2003;3(2):257-265.
9. Javan M, Ahmadiani A, Semnianian S, Kamalinejad M. Antinociceptive effects of *Trigonella foenum-graecum* leaves extract. J Ethnopharmacol 1997;58(2):125-129.
10. Ahmadiani A, Javan M, Semnianian S, Barat E, Kamalinejad M. Anti-inflammatory and antipyretic effects of *Trigonella foenum-graecum* leaves extract in the rat. J Ethnopharmacol 2001;75(2-3):283-286.
11. Winter CA, Risley EA, Nuss GW. Carrageenin-induced edema in hind paw of the rats as an assay for antiinflammatory drugs. Proc Soc Exp Biol Med 1962;111:544-547.
12. Rimbau V, Cerdan C, Vila R. Antiinflammatory activity of some extracts from plants used in the traditional medicine of North-African countries (II). Phytother Res 1999;13:128-132.
13. Sur P, Das M, Gomes A, et al. Trigonelle foenum-graecum (Fenugreek) seed extract as an antineoplastic agent. Phytother Res 2001;15:257-259.

14. Kouadio F, Kanko C, Juge M, et al. Analgesic and antiinflammatory activities of an extract from *Parkia biglobosa* used in traditional medicine in the Ivory Coast. *Phyther Res* 2000;14:635-637.
15. Handa SS, Sharma A. Hepatoprotective activity of andrographolide from *Andrographis paniculata* against carbontetrachloride. *Indian J Med Res [B]* 1990;92:276-283.
16. Shenoy KA, Somayaji SN, Bairy KL. Hepatoprotective effects of *Ginkgo biloba* against carbon tetrachloride induced hepatic injury in rats. *Ind J Pharmacol* 2001;33:260-266.
17. Horváth MÉ, González-Cabello R, Blázovics A, et al. Effect of silibinin and vitamin E on restoration of cellular immune response after partial hepatectomy. *J Ethnopharmacol* 2001;77:227-232.
18. Shang MY, Cai SQ, Lin WH, Wang MC, Park JH. Studies on chemical constituents from the seed of *Trigonella foenum-graecum*. *Zhongguo Zhong Yao Za Zhi* 2002;27(4):277-279.
19. Yang WX, Huang HY, Wang YJ, Jia ZY, Li LL. Study on chemical constituents in total saponin from *Trigonella foenum-graecum*. *Zhongguo Zhong Yao Za Zhi* 2005;30(18):1428-1430.
20. Yoshikawa M, Murakami T, Komatsu H, et al. Medicinal foodstuffs. IV. Fenugreek seed. (1): structures of trigoneosides Ia, Ib, IIa, IIb, IIIa, and IIIb, new furostanol saponins from the seeds of Indian *Trigonella foenum-graecum* L. *Chem Pharm Bull (Tokyo)* 1997;45(1):81-87.