

eISSN: 09748369, www.biolmedonline.com

The histological effects of mixed diet containing *Pausinystalia yohimbe* ground stem bark on the kidney of adult Wistar rats (*Rattus norvegicus*)

*AO Eweka, FAE Om'Iniabohs, O Momodu

Department of Anatomy, School of Basic Medical Sciences, College of Medical Sciences, University of Benin, Benin City, Edo State, Nigeria.

*Corresponding Author: andreweweke@yahoo.com

Abstract

The effect of yohimbine, used as an aphrodisiac and for the treatment of erectile dysfunction in males on the kidneys of adult Wistar rat was investigated. Both adult male and female Wistar rats (n=30), average weight of 190g, were randomly assigned into three treatments (n=24) and control (n=6) groups; labeled A (n=8), B (n=8), C (n=8) and D, control (n=6) groups respectively and were administered with ground stem bark of *Pausinystalia yohimbe* in various amounts; Group A: 30g, Group B: 50g and Group C: 70g mixed with equal amount of feeds (550grams/day of growers' mash) for a period of 14 days. The control rats received equal amount of the growers' mash without ground stem bark of *Pausinystalia yohimbe* added. The growers' mash was obtained from Edo Feeds and Flour Mill Ltd, Ewu, Edo State and the rats were given water liberally. The rats were sacrificed on day fifteen of the experiment. The kidneys were carefully dissected out and quickly fixed in 10% buffered formaldehyde for routine histological procedures. The histological findings in the treated groups showed distortion of the renal cortical structures, vacuolations appearing in the stroma and some degree of cellular necrosis, with degenerative and atrophic changes as compared to the control group. These findings indicate that yohimbine may have some deleterious effects on the kidneys of adult Wistar rats at varied doses. It is recommended that further studies aimed at corroborating these findings be carried out.

Keywords: *Pausinystalia yohimbe*; renal corpuscle; vacuolations; cellular necrosis; cyto-architecture; Wistar rats.

Introduction

Many plants have been screened for their medicinal properties; this includes yohimbine, which is an alkaloid chemically similar to reserpine. It is gotten from the bark of the yohimbe tree; it possesses alpha-adrenergic blocking properties and is used as the hydrochloride as a sympatholytic and, mydriatic, and for the treatment of impotence (Dorland's Medical Dictionary for Health Consumers, 2007). Sexual dysfunction is a serious medical and social problem that occurs in 10%-52% in men and 25%-63% in women. Numerous central and peripheral neural circuits control sexual activity. Impairment of one or more of these functional circuits may have a significant impact on personal, social and biological relationships. Although several aspects of sexual motivation and performance are known, a complete picture of the various factors that control human sexual activity is still unknown. The available drugs and treatments have limited efficacy, unpleasant side

effects and contraindications in certain disease conditions. A variety of botanicals is known to have a potential effect on the sexual functions, supporting older claims and offering newer hopes (Tharakan and Manyam, 2005).

Yohimbine, indole alkaloid is either the active ingredient obtained from the bark of the tree *Pausinystalia yohimbe* or from the root of *Rauwolfia* which has been known as an aphrodisiac compound since before the last century (Hunner, 1926; Willaman, 1970; Lebeouf et al., 1981). The plant is native to the tropical rain forest of West Africa. The dried stem bark is widely used in North Eastern Nigeria for the treatment of erectile dysfunction and as an aphrodisiac (Jacks et al., 2007).

The tree of *Pausinystalia yohimbe* (Pierre ex Bielle) is a tall seldom-exceeding 18m in height and 1.2m in girth. It is abundant in the forest. The Bark is grey, smooth; slash creamy-white. It has fibrous leaves that are 7 – 20 cm long by 3.5 – 7.5 cm broad, the shape of the

Leaves varies from ellipsoid to oblong, sharply acuminate, narrowly cuneate, and rather thin; with 5-10 pairs of lateral veins. Its' stalk is short, about 2.5cm long or almost stalkless. Its Flowers (May to Sept.) are white, scented with axillaries and terminal panicles. The fruit (Jan to Mar) is spindle-shaped, measuring up to 2cm long with narrowly elongated winged seeds. It is found to extend from southwestern Nigeria to Gabon and Zaire. Yoruba call it 'Agbo idagbon' while Edo call it 'nikiba' (Kaey et al., 1989).

Several pharmacological and physiological properties of yohimbine have been described (Golberg and Roberson, 1983; Sala et al., 1990; Riley, 1994; Ernst and Pittler, 1998; Sharabi, 2004). The best documented activity of yohimbine was the antagonism of the α -adrenoreceptor (Golberg et al., 1983). Current hypothesis on the beneficial mechanism of the action of yohimbine on sexual activities mainly points to a central mechanism of action (Sonda et al., 1990). This suggestion is based chiefly upon results from animal studies showing that yohimbine increase sexual motivation even in sexually exhausted rats, due to its action on the central α -adrenoreceptors located in locus coeruleus (Rodriguez-Manzo and Fernandez-Guasti, 1995).

In clinical studies, this hypothesis was however not convincing because when tested, yohimbine did not ameliorate sexual desire or thought in double-blind placebo-controlled safety and efficacy trials with yohimbine hydrochloride in the treatment of erectile dysfunction in men (Vogt, 1997). In addition to the blockage of α -adrenoreceptor, yohimbine is able to not only induce enhancement of sympathetic outflow from the central nervous system but also increase catecholamine release from peripheral sympathetic nerve terminals (Langers, 1974). The latter could be detrimental for penile erection because human corporal smooth muscle is endowed with postsynaptic α -adrenoreceptor that predominantly belong to the α -sub type and mediate cellular contraction (Hedlund et al., 1985). An alternative hypothesis is that yohimbine also acts at the peripheral level, blocking α -adrenoreceptor. Indeed recent evidence obtained by binding and functional studies suggest that not only the α_2 but also the α_1 -adrenoreceptor mediating contractility are present in the human and rabbit corpora

cavanosa and that yohimbine might interact with both (Traish et al., 1997). Hence, it is possible that the positive effect of yohimbine on penile erection is not only related to central effect but also to peripheral sympatholytic activity (Wagner and Saenz de Tejada, 1998). Wagner and Saenz de Tejada further stated that yohimbine has only a modest effect on psychogenic erectile dysfunction and none on organic erectile dysfunction. This view was supported by the recent American Urological Association guidelines on treatment of organic erectile dysfunction, which state "the outcome data for yohimbine clearly indicate a marked placebo efficacy (Montague et al., 2007). However, organic and psychogenic causes of erectile dysfunction often overlap, which makes differentiation difficult. Our meta-analysis of all double blind, randomized, placebo controlled trials of yohimbine for erectile dysfunction found a significant improvement in patients treated with yohimbine {(odds ratio 3.85, 95% confidence interval 2.22 to 6.67) (Ernst and Pittler, 1998)}. These data, which also relate to men with less well-defined causes of erectile dysfunction, suggest that yohimbine is an effective, non-invasive option for initial drug treatment.

It is important to mention that there are no reliable clinical studies available for administration of yohimbine bark (Guay et al., 2002). Report from studies show that yohimbine is able to increase salivary secretion in both animals and man (Bagheri et al., 1997). Result on the effect of aqueous extract of *Pausinystalia macroceras* on testicular activity suggest that the extract could support spermatogenesis at low dose level while at higher doses; it decreased spermatogenic activity grossly (Jacks et al., 2007).

Research has shown that yohimbine administration increases lipolysis by antagonizing the anti lipolytic activity of α_2 -adrenoreceptors on fat cells (Galitzky et al., 1988; Galitzky et al., 1990; Berlan et al., 1991). This blockade of the α -receptors by yohimbine results in increased fat mobilization from these stubborn cells and increase blood free fatty acid concentration during and after exercise to ensure a high rate of fat metabolism. Interestingly, the most positive effects of yohimbine on fat loss are seen in females (Kucio et al., 1991). Contrary to the lipolytic activity of

yohimbine, a control study suggested that 43mg/day yohimbine had no effect in body weight, body fat and cholesterol levels (Sax, 1991). Yohimbine is also an appetite suppressant, and decreases energy intake in both lean and obese mice (Currie and Wilson, 1992).

It has been shown that yohimbine induced an antidiuretic effect without changes in renal hemodynamic (Farjam, 1989). Contrary to these later findings, aqueous extract of *Pausinystalia yohimbe* was observed to possess endothelin-like action and affect nitric oxide release in renal circulation. This resulted in increase mean blood pressure and renal medullary blood flow (Ajayi, 2003). Studies of the effect of yohimbine on the renal sympathetic activity and renal norepinephrine release in anaesthetized rabbits showed increase in total norepinephrine spillover were much higher than increase of renal spillover. Yohimbine 1mg/kg+0.2mg/kg caused slight central sympathoexcitation. In addition, it enhanced the renal and total spillover of norepinephrine at any given firing rate or renal sympathetic nerves (Szabo et al., 1992). Records within reach show that there is no research to ascertain the histological effect of yohimbine on kidney tissue.

The kidney is a paired organ located in the posterior abdominal wall, whose functions include the removal of waste products from the blood and regulation of the amount of fluid and electrolytes balance in the body. As in humans, the majority of drugs administered are eliminated by a combination of hepatic metabolism and renal excretion (Katzung, 1998). The kidney also plays a major role in drug metabolism, but its major importance to drugs is still its excretory functions. This study will further corroborate or disprove the toxic effects of *yohimbine* in organs other than sex organs, with a view to advising the consumers on the inherent dangers of excessive consumption of the aphrodisiac.

Materials and Methods

Plant Material

Pausinystalia Yohimbe stem bark was obtained from compartment 54, Okomu Forest Reserve

(Okomu National Park) at Arakhuan, Udo of Edo State. The tree was identified and authenticated by Mr. Abibi (Department of Pharmacognosy) and Dr. Aigbokhan (Department of Botany) both of the University of Benin. A specimen voucher: ANA /001/PY, of the bark of *Pausinystalia yohimbe* was made and deposited in the Department of Anatomy, School of Basic Medical Sciences, University of Benin, Benin City. The harvested fresh bark was sun dried and ground into a fine powder. The dried material (2.3kg) was placed in a stainless-steel tray, and concentrated in an air-circulating oven at 42°C until very dry. The resultant dried ground substance was placed into small glass dishes and stored at 28°C in an incubator for further studies.

Animals

Both adult male and female Wistar rats (n=30) average weight of 190g were randomly assigned into three treatments (n=24) and control (n=6) groups; labeled A (n=8), B (n=8), C (n=8) and D, control (n=6) groups respectively and were housed in a cross ventilated room in the Animal Holdings of the Department of Anatomy, School of Basic Medical Sciences, University of Benin, Benin City, Nigeria.. The temperature of the room is about 28° c and the lighting of the room was organized to give 12 hours of light and 12 hours of dark. They were administered with ground stem bark of *Pausinystalia yohimbe* in various amounts; Group A: 30g, Group B: 50g and Group C: 70g of ground stem bark mixed with equal amount of feeds (550grams/day of growers' mash) for a period of 14 days. The control rats received equal amount of the growers' mash without ground stem bark of *Pausinystalia yohimbe* added. The growers' mash was obtained from Edo Feeds and Flour Mill Ltd, Ewu, Edo State and the rats were given water liberally. The rats were sacrificed on day fifteen of the experiment. The kidneys were carefully dissected out and quickly fixed in 10% formal saline for histological procedures. The rats gained maximum acclimatization (2 weeks) before actual commencement of the experiment. The 30g, 50g and 70g ground stem bark of *Pausinystalia yohimbe* doses were chosen and extrapolated in this experiment based on the indiscriminate use of the plant here in Nigeria and on the pilot study carried out before the actual commencement of the work.

Histological Study

Renal tissues were dehydrated in an ascending grade of alcohol (ethanol 70%), cleared in xylene and embedded in paraffin wax after the method of Drury and Wallington (1980). Serial sections of 7 microns thick were obtained using a rotatory microtome. The deparaffinised sections were stained routinely with hematoxylin and eosin. Photomicrographs of the desired results were obtained using digital research photographic microscope in the University of Benin research laboratory.

Results

The photomicrograph of the kidney in the control group (D) showed normal histological features. The section indicated a detailed cortical parenchyma and the renal corpuscles appeared as dense rounded structures with the glomerulus surrounded by a narrow Bowman's spaces (fig. 1).

The kidneys of the animals in group A treated with 30g per day, of the ground stem

bark of *Pausinystalia yohimbe* revealed some level of cyto-architectural distortion of the cortical structures as compared with the control (fig. 2).

The kidney sections of animals in group B treated with 50g per day, of the ground stem bark of *Pausinystalia yohimbe* revealed marked distortion of cyto-architecture of the renal cortical structures, and degenerative and atrophic changes. The renal corpuscles were less identified and the Bowman's spaces were sparsely distributed as compared to the control group (fig. 3).

The kidney sections of animals in group C treated with 70g per day, of the ground stem bark of *Pausinystalia yohimbe* revealed marked distortion of cyto-architecture of the renal cortical structures, and degenerative and atrophic changes. There were vacuolations appearing in the stroma. The renal corpuscles were less identified and the Bowman's spaces were sparsely distributed as compared to the control group (fig. 4).

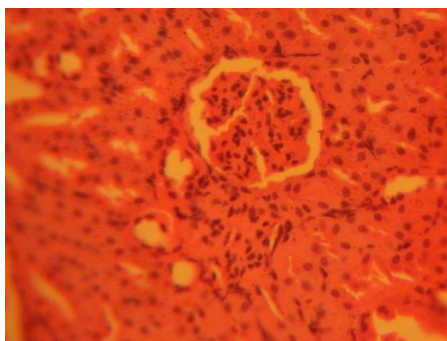


FIGURE 1: Control section of kidney; this shows cortical parenchyma to consist of dense rounded structures, the glomeruli, surrounded by narrow Bowman's capsular spaces. (Mag. X200)

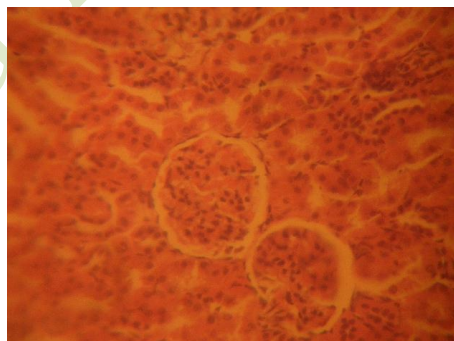


FIGURE 2: Photomicrograph of treatment section of the kidney of rats that received 30g of the ground stem bark of *Pausinystalia yohimbe* (Mag. x200)

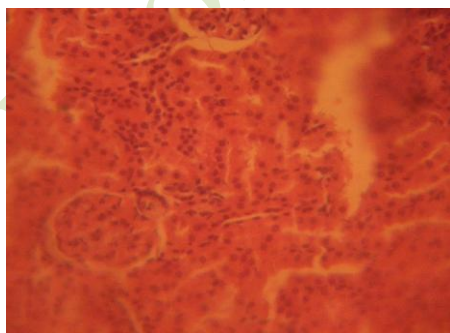


FIGURE 3: Treatment section of the kidney of rats that received 50g of the ground stem bark of *Pausinystalia yohimbe* (Mag. x200)

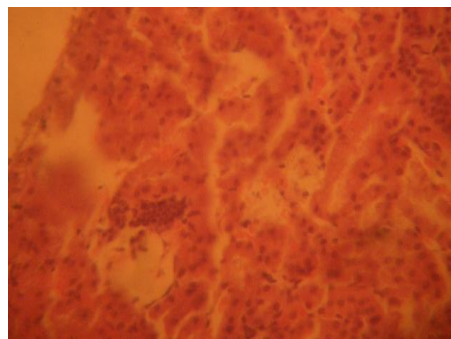


FIGURE 4: Treatment section of the kidney of rats that received 70g of the ground stem bark of *Pausinystalia yohimbe* (Mag. x200)

Discussion

The results (H & E) reactions showed that administration of the ground stem bark of *Pausinystalia yohimbe* caused varying degree of cyto-architectural distortion and reduction in the number of renal corpuscle in the treated groups compared with the control group. There were degenerative and atrophic changes observed in the kidneys of rats that received the higher doses (50g and 70g) of the ground stem bark of *Pausinystalia yohimbe*.

It may be inferred from the present results that higher doses of *Pausinystalia yohimbe* resulted in degenerative and atrophic changes observed in the renal corpuscle. The actual mechanism by which *Pausinystalia yohimbe* induced cellular degeneration observed in this experiment needs further investigation. The necrosis observed is probably due to the high concentration of the *Pausinystalia yohimbe* on the kidney. Pathological or accidental cell death is regarded as necrotic and could result from extrinsic insults to the cell as osmotic thermal, toxic and traumatic effect (Farber et al., 1981). Physiological cell death is regarded as apoptotic and organized programmed cell death (PCD) that is mediated by active and intrinsic mechanisms. The process of cellular necrosis involves disruption of membranes, as well as structural and functional integrity. Cellular necrosis is not induced by stimuli intrinsic to the cells as in programmed cell death (PCD), but by an abrupt environmental perturbation and departure from the normal physiological conditions (Farber et al., 1981).

The experiment also revealed some histological abnormalities and cyto-architectural distortion of the renal cortical structures, which may be ascribed to the effects of ground stem bark *Pausinystalia yohimbe* on the kidney. The renal cortical structures are distorted as against that of the control rats. The results of this experiment suggest that the distortion of the cyto-architecture of the kidney could have been associated with functional changes that may have been detrimental to the health status of the animal that may have been due to the interference of *Pausinystalia yohimbe* on the kidney. In cellular necrosis, the rate of progression depends on the severity of the environmental insults: the greater the severity of the insult, the more rapid the progression of

cellular injury. The principle holds true for toxicological insult to the brain and other organs (Ito et al., 2003). It may be inferred from the present study that prolonged administration and higher doses of *Pausinystalia yohimbe* resulted in increased toxic effect on the kidney. The kidney sections treated with higher doses of *Pausinystalia yohimbe* were most severely affected in this experiment.

Conclusion

The results obtained in this study indicate that the administration of 30g, 50g and 70g per day of the ground stem bark of *Pausinystalia yohimbe* to adult Wistar rats causes disruptions and distortions of the cyto-architecture of the kidneys. This resulted in the cellular necrosis, and sparsely distribution of the Bowman's spaces. These results suggest that the functions of the kidney may have been adversely affected. It is recommended that further studies be carried out to examine these findings.

References

- Ajayi AA, Newaz M, Hercule H, Saleh M, Bode CO, Oyekan AO, 2003. Endothelin-like action of *Pausinystalia yohimbe* aqueous extract on vascular and renal regional hemodynamics in Sprague Dawley rats. *Experimental Clinical Pharmacology*, 25(10): 817.
- Bagheri H, Schmit L, Barisn M, 1997. A comparative study of the effects of yohimbin and anetholtsithione on the salivary secretion in depressed patients treated with psychotropic drugs. *European Journal of Clinical Pharmacology*, 52 (15): 339-342.
- Berlan M, Galitzky J, Riviere D, Foureau M, Tran MA, Flores R, Louvet JP, Houin G, Lafontan M, 1991. Plasma catecholamine levels and lipid mobilization induced by yohimbine in obese and non-obese women. *International Journal of Obesity*, 5: 305-15.
- Currie PJ, Wilson LM, 1992. Yohimbine attenuates clonidine-induced feeding and macronutrient selection in genetically obese (ob/ob) mice. *Pharmacological and Biochemical Behaviour*, 43 (4): 1039-46.
- Dorland's Medical Dictionary for Health Consumers, 2007. Saunders, an imprint of Elsevier, Inc.
- Drury RAB, Wallington EA, Cameron R, 1967. *Carleton's Histological Techniques*: 4th ed. Oxford University Press, NY, U.S.A., 279-280.

- Ernst E, Pittler MH, 1998. Yohimbine for erectile dysfunction: a systematic review and meta-analysis of randomized clinical trials. *Journal of Urology*, 159: 433-436.
- Farber JL, Chien KR, Mitnacht S, 1981. Myocardial ischemia: pathogenesis of Irreversible cell Injury in ischemia. *American Journal of Pathology*, 102: 271-281.
- Farjam A, Greven J, 1989. Effects of the alpha 2-adrenoreceptor antagonists' yohimbine and idazoxan on kidney function in intact and diabetes insipidus rats. *Urology International*, 44 (5): 25-9.
- Galitzky J, Taouis M, Berlan M, Riviere D, Garrigues M, Lafontan M, 1988. Alpha 2-antagonist compounds and lipid mobilization: evidence for a lipid mobilizing effect of oral yohimbine in healthy male volunteers. *European Journal of Clinical Investigation*, (6): 587-94.
- Galitzky J, Riviere D, Tran MA, Montastruc JL, Berlan M, 1990. Pharmacodynamic effects of chronic yohimbine treatment in healthy volunteers. *European Journal of Clinical Pharmacology*, 39 (5): 447-51.
- Goldberg MR, Robertson D, 1983. Yohimbine: a pharmacological probe for study of the alpha 2-adrenoreceptor. *Pharmacology Review*, 35: 143-180.
- Guay AT, Spark RF, Jacobson J, Murray FT, Geisser ME, 2002. Yohimbine treatment of organic erectile dysfunction in a dose-escalation trial. *International Journal of Impotence Research*, 14(1): 25-31.
- Hudlund H, Andersson KE, 1985. Comparison of the response to drugs acting on adrenoreceptors and muscaric receptors in human isolated corpus cavernosum and cavernous artery. *Journal of Australian Pharmacology*, 5: 81-88.
- Hunner MA, 1926. Practical treatise on disorder of sexual function of the male and female. FA Davis: Philadelphia.
- Jacks TW, Asala AS, Priasad J, 2007. Testicular enhancement activity of aqueous extract of *Pausinystalia macroceras* stem-bark in Wistar rats. *Journal of Anatomical Sciences*, 1: 3-6.
- Kaey RWJ, Onochie FA, 1964. Trees of Nigeria: A Textbook: 2nd edition, Standfield, DP: 413-425.
- Katzung BG, 1998. Basic and Clinical Pharmacology, 7th edition, Appleton and Lange. Stamford CT. pp. 372-375.
- Kucio C, Jonderko K, Piskorska D, 1991. Does yohimbine act as a slimming drug? *Israel Journal of Medical Sciences*, 10: 550-6.
- Langer S, 1974. Presynaptic regulation of catecholamine release. *Biochemistry and Pharmacology*, 23: 1793-1800.
- Lebeouf M, Cave A, Mangeney P, Bouquet A, 1981. Alkaloids of *Pausinystalia macroceras*, *Planta Medica*, 41: 374-378.
- Montague DK, Barada JH, Belker M, Levine LA, Nadig PW, Roehborn CG, 1996. Clinical guidelines panel on erectile dysfunction: summary report on the treatment of organic erectile dysfunction. *Journal of Urology*, 156: 2007-2011.
- Riley AJ, 1994. Yohimbine in the treatment of erectile disorder. *British Journal of Clinical Pharmacology*, 48: 133-136.
- Rodriguez-Manzo G, Fernandez-Guasti A, 1995. Participation of the central noradrenergic system in the re-establishment of copulatory behaviour of sexually exhausted rats by yohimbine, naloxone, and 8-OH-DPAT. *Brain Research Bulletin* 5, 38 (4): 399-404.
- Sala M, Braida D, Leone MP, Calcaterra P, Monti S, Gori E, 1990. Central effect of yohimbine on sexual behaviour in the rat. *Physiology and Behaviour*, 47: 165-173.
- Sax L, 1991. Yohimbine does not affect fat distribution in men. *International Journal of Obesity*, 15(9): 561-5.
- Sonda LP, Mazo R, Chancellor MB, 1990. The role of yohimbine for the treatment of erectile impotence. *Journal of Sex and Marital Therapy*, 1: 15-21.
- Szabo B, Schramm A, Starke K, 1992. Effect of yohimbine on renal sympathetic nerve activity and renal norepinephrine spillover in anesthetized rabbits. *Journal of Pharmacology and Experimental Therapy*, 260(2): 780-788.
- Tharakan B, Manyam BV, 2005. Botanical therapies in sexual dysfunction. *Phytotherapy Research*, 19(6): 457-63.
- Traish AM, Moreland RB, Uang YU, Goldstein I, 1997. Extension of functional α 2-adrenergic receptor subtypes in human corpus cavernosum and in cultured trabecular smooth muscle cells. *Receptor and Signal Transduction*, 7: 55-67.
- Vogt HJ, Brandl P, Kockott G, 1997. Double-blind placebo-controlled safety and efficacy trial with yohimbine hydrochloride in the treatment of nonorganic erectile dysfunction. *International Journal of Impotence Research*, 9(3): 155-61.

Wagner G, Saenz de Tejada I, 1998. Update on male erectile dysfunction. *British Medical Journal*, 316: 678-682.

Hui-Lin L, Willaman JJ, 1972. Recent trend in alkaloid hunting. *Economic Botany*, 26 (1): 61-67.

Biology and Medicine